

Evaluation of the efficacy of an oral spray formulation of hyaluronic acid and amino acids in secondary 'burning mouth syndrome' from local or general causes, with specific regard to gender

Laura Lanza¹, Carlo Emilio Falco¹, Caterina Ermio²

¹Department of Otorhinolaryngology, Vigevano and Voghera Hospitals, ASST Pavia, Italy; ²Department of Neurology, Lamezia Terme Hospital, ASP Catanzaro, Italy

Received 7 October 2019; accepted 17 November 2020

Summary. Burning mouth syndrome is associated with a significant discomfort for the patient. The following research assessed and validated the use of a medical device designed to facilitate the healing of the oral mucosa, and therefore to reduce any undesirable effects induced by the inflammation and ulceration of the mucous membranes. Among the latest generation of medical devices, hyaluronic acid and amino acid preparations stand out. Several studies have shown the regenerative effect of this association on the mucous membranes of the oral cavity. A prospective study was carried out to evaluate the efficacy of a new oral formulation based on sodium hyaluronate and amino acids (Mucosamin®) versus a bicarbonate solution in the clinical management of patients with burning mouth syndrome secondary to local or systemic conditions, with a particular focus on the female population, where the prevalence of burning mouth syndrome is significantly higher. Based on the data obtained, the study product can be recommended for local treatment, to reduce the degree of de-epithelialization of the mucosa. The results demonstrate that the solution based on hyaluronic acid and amino acids has shown to improve at all control points, decrease and healing of lesions, patient satisfaction and reduction of pain sensation.

Key words. Burning mouth syndrome, hyaluronic acid, amino acids, stomatopyrosis, mucositis, gender.

Valutazione dell'efficacia di una formulazione in spray orale a base di acido ialuronico e aminoacidi nella 'burning mouth syndrome' di tipo secondario da cause locali o generali, con particolare riguardo al genere

Riassunto. La sindrome della bocca urente comporta un importante discomfort per il paziente. A seguito di ciò, la ricerca ha progressivamente validato dei dispositivi medici atti a facilitare la guarigione della mucosa orale e quindi a ridurre gli effetti indesiderati indotti dalla flogosi e dall'ulcerazione delle mucose stesse. Tra i dispositivi di ultima generazione spiccano i preparati a base di acido ialuronico e aminoacidi. Vari studi sono presenti in letteratura sull'efficacia riparativa di tale associazione a livello delle mucose del cavo orale. Nel presente lavoro è stato realizzato uno studio prospettico per valutare l'efficacia di una nuova formulazione in spray orale a base di sodio ialuronato e aminoacidi (Mucosamin®) versus una soluzione di bicarbonato nel decorso clinico di pazienti che presentano sindrome della bocca urente di tipo secondario conseguente a manifestazioni

patologiche locali o sistemiche con particolare riguardo alla popolazione femminile che presenta una prevalenza significativamente più spiccata per la problematica. In base ai dati ottenuti si può consigliare il prodotto in studio nella medicazione locale per ridurre il grado di disepitelizzazione della mucosa. La soluzione a base di ialuronato e aminoacidi spray sembra influire positivamente oltre che sulle lesioni obiettive, anche sul grado di soddisfazione e sulla riduzione della sensazione soggettiva di dolore.

Parole chiave. Sindrome della bocca urente, acido ialuronico, aminoacidi, stomatopirosi, mucosite, genere.

Introduction

Due to its expression and presentation, characterized by a clinical-symptomatological picture that gives spontaneous burning sensation affecting tongue, palate, lips and/or other mucous membranes of the oral cavity, burning mouth syndrome can be considered a manifestation of orofacial atypical pain. A prevalence in the general population ranging from 0.7% to 3.7% and an average age of about 60 years have been described, with a maximum peak in women over 50 years of age between 18% and 33%.¹⁻³

Burning mouth syndrome is mostly classified according to etiology and is divided into primary or idiopathic stomatopyrosis – where organic causes and burning mouth are not identified – or secondary stomatopyrosis, resulting from local or systemic pathological manifestations.^{2,4-6}

Among the possible local causes taken into consideration in recent years are lesions or irritative states of the mucous membrane of the oral cavity, or lesions due to inflammatory and infectious mechanisms, allergic contacts, immune and/or degenerative processes, tobacco consumption in all its forms, smoking marijuana and its derivatives, regular consumption of alcohol, large consumption of caffeine-containing drinks (coffee and cola) and other stimulants, use of mouthwashes or rinses containing alcohol or powerful detergents, regular ingestion of very hot, very spicy or acidic foods (lemon, grapefruit, other citrus fruits), xerostomia, oral candidiasis, oral lichen planus and, finally, microtraumatic

components (trauma from prostheses, occlusal disorders) and vascular disorders.^{7,8}

Systemic causes include gastroesophageal reflux, autoimmune diseases, Sjogren's syndrome, outcomes of radiation or cytostatic therapy, the use of certain drugs (ACE-inhibitors, levodopa, etc), polyvitamin deficiencies (B6, B12, folic acid), diabetes mellitus, menopause, anemia, iron deficiency, hypothyroidism, HIV infection.⁵

Both local and general causes induce inflammatory changes in the integrity of the patient's mucosal tissues of the oral cavity, tongue and oropharynx; it seems that the inflammatory process of the epithelium is preceded by damage to the vascular component and to the connective tissue in the submucosa.

For burning mouth syndrome or secondary stomatopyrosis consequent to local or systemic pathological manifestations, the pharmaceutical industry has gradually developed medical devices to facilitate the healing of the oral mucosa, which presents lesions such as ulcerations, canker sores, whitish mycoses, boils, submucosal ecchymoses, arborescence, erythema, atrophy, leukoplakia, post-traumatic erosion, edema.^{9,10}

Preparations based on hyaluronic acid (HA) and amino acids stand out among the most recent therapeutic innovations.

HA is found in high concentrations in the granulation tissue, where it promotes cell migration and proliferation, as well as the organization of the granulation tissue itself. The mixture of HA and amino acid has been shown to act on the ulcerative phase of mucositis – reducing both pain and burning – and on the regenerative phase of the mucositis itself.¹¹⁻¹³

The aim of this clinical trial was the evaluation of the efficacy of a new oral spray based on sodium hyaluronate and amino acids (Mucosamin®) in the clinical course of patients presenting with burning mouth syndrome or

secondary stomatopyrosis following local pathological or systemic manifestations, with particular focus on the female population (among whom prevalence is significantly greater) referring to the Otolaryngology department of the Hospital of Voghera (ASST of the Province of Pavia).

Materials and methods

The study was conducted on patients >18 years of age, of both sexes, who underwent ENT (ear, nose and throat) examination + biopsy of the most relevant lesion of the oral cavity at the Voghera Hospital (ASST of the Province of Pavia) in the period between October 1, 2015 and September 30, 2016.

All patients had burning mouth syndrome or stomatopyrosis secondary to local or general causes, as well as unique or multiple mucosal changes (Table 1) and burning pain in the oral cavity for a minimum of one month up to 6 months.

Exclusion criteria were: burning mouth syndrome or primary stomatopyrosis, neurological or psychiatric conditions, systemic disorders or current medical therapies capable of interfering with healing processes.

The trial included 60 patients, distributed in two groups (A and B), randomized by blocks of 6, in order to ensure gender equivalence. Each group consisted of 30 patients (15 males and 15 females). Group A (the study group) was prescribed local application of the Mucosamin® spray 3 times a day after the main meals for 1 month; group B (the control group) was prescribed oral rinses with sodium bicarbonate diluted in water (1 glass of water + 2 spoons of baking soda).

For the control group we used sodium bicarbonate since, by creating an alkaline environment, it stimulates

Table 1. Histologic characteristics of the 2 groups

Histology	Group A		Group B	
	Males	Females	Males	Females
Prosthetic trauma friction keratosis or hyperkeratosis and/or acanthosis or parakeratosis	5	7	3	10
Lymphoid or pseudoepitheliomatous hyperplasia	1	2		
Lymphoplasmacellular and granulocytic inflammatory infiltrates and atypia	3		7	1
Reactive-inflammatory fibrosis			2	
Pseudoepitheliomatous hyperplasia and lymphogranulocytic inflammation	2		1	
Cytopathic lesions with suspected viral etiology	2	4	2	2
Histiocytic or lymphohistiocytic or granulocytic cell infiltrate	2	1		2
Lichen planus		1		

the bacterial flora of the oral cavity, and is therefore a mouth-disinfecting antibacterial substance.

The start of treatment coincided with the day the patient was visited and received an oral cavity biopsy.

The primary outcome was the clinical criterion for improving mucosal objectivity by at least one degree of the Oral Mucositis Assessment Scale (OMAS), assessed by means of an otorhinolaryngological examination after 7, 15 and 30 days from inclusion.

Subjective parameters, assessed through questionnaires, were also detected as secondary outcomes: the degree of patient satisfaction quantified on a scale of 1 to 4 (negative, modest, good and excellent) and the pain measured with a one-dimensional verbal rating scale (VRS) instead of a numerical (NRS) one, selected for reasons of simplicity and practicality (verbal use without any paper support), giving space to the qualitative description (0 no pain, 1 mild pain, 2 moderate pain, 3 strong pain, 4 unbearable pain) and considering as "improved" the subjects who went down at least one point. As regards the degree of satisfaction, an increase of at least one point on the scale was judged positive as well as an improvement.

By way of example, Figure 1 contains the images of the starting clinical pictures of some of the patients included in the study.

To 'measure' the extent of the phenomenon in the various treatment contexts, over the past thirty years literature has proposed a wide range of scales. The most widely used are the 'numeric' ones, which assign a grade based on the severity of specific signs or symptoms, are

easy to use, and have a strong propensity for objectivity and reproducibility.^{1,6,14}

The oral mucositis degree assessment (mucosal changes) can therefore be obtained through the use of scales, which allow to identify the severity of the complication and are therefore essential while selecting the patient's treatment.

The assessment scales most commonly used at international level are the WHO (World Health Organization) scale and the OMAS scale, which evaluate the functional alterations and score differently, based on severity.

We decided to use the OMAS scale (Table 2), because it has been designed and validated for clinical trials and is therefore the most specific and sensitive reference for the evaluation of oral mucositis in all its mucosal alteration expressions, and is still valid for its characteristics of simplicity, reproducibility and applicability in multiple contexts. It takes into consideration many features, referring to specific objectivity and morphological aspects, and it is therefore precise and objective, besides being an internationally approved scale.

The overall evaluation of mucositis according to the OMAS scheme is expressed by adding the scores (from 0 to 5) relating to the degree of erythema, ulcers and pseudo-membranes in certain regions of the oral cavity, that evaluate epithelialization/de-epithelialization.

The evaluation of the state of the mucous membranes was performed each time, through an inspection of the oral cavity performed in the same room and with the same light.

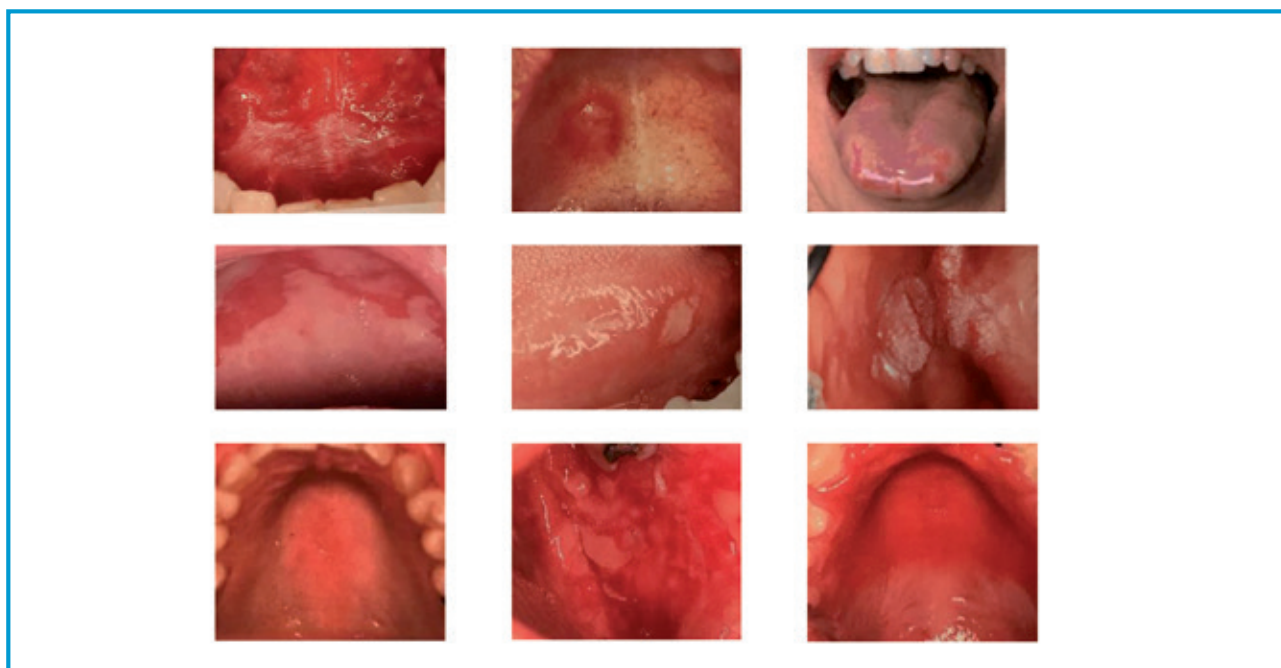


Figure 1. Examples of starting clinical pictures.

Table 2. The OMAS scale

Erythema	0	1	2	
	No change in the color of the mucosa	Increased intensity of the color of the mucosa	Bright blood-colored mucosa	
		+		
Ulcerations/ pseudomembranes	0	1	2	3
	No lesions	Surface areas of lesions smaller than 1 cm ²	Surface areas of lesions larger than 1 cm ² and equal to or smaller than 3cm ²	Surface areas of lesion larger than 3 cm ²
		=		

Given the small sample size, the statistical analysis was conducted with univariate tests, using the T-Student for continuous variables and the Chi square for discrete ones. The difference between the groups was assessed considering the statistically significant result for values of $p < 0.05$.

Results

Patients were aged between 42 and 93 (average 65.21; median 66.1), without any differences between the groups. The duration of symptoms also did not differ between the groups.

The distribution of the subjective evaluation of pain did not differ between the groups (Table 3).

The distribution of the lesions showed unique or multiple oral mucosal alterations, with a surface from a few mm up to about three cm, and an increase in the intensity of the color of the mucosa itself, until becoming strongly hyperemic; lesions had a comparable frequency in the 2 groups and between the 2 genders ($p > 0.05$) (Table 4).

The mucosal objectivity showed an improvement trend in all groups. In particular:

- group A: improvement of mucosal objectivity at day 7 in 38% of patients, at day 15 in 53% and at day 30 in 79% of patients;
- group B: improvement of mucosal objectivity at day 7 in 20% of patients, at day 14 in 20% and at day 30 in 57% of patients.

Objective evaluations of the mucous membranes of the oral cavity, assessed by the OMAS scale, showed a reduction in the degree of de-epithelialization. From the comparison between the two groups, the reduction of de-epithelialization is greater in the study group and among women, with highly significant results at day 7, day 15 and month 1 (Figure 2).

Table 3. General characteristics of patients

	Group A		Group B	
	Males	Females	Males	Females
Average age	63.02	67.40	62.10	68.10
Average duration	3.93	4.27	3.80	4.13
<i>VRS Pain scale (sample size)</i>				
Grade 2	4	1	4	3
Grade 3	9	11	10	9
Grade 4	2	2	1	3

Table 4. OMAS grade at enrolment

	Group A		Group B	
	Males	Females	Males	Females
0	0	0	0	0
1	1	0	1	1
2	6	6	6	4
3	6	8	7	9
4	2	1	1	1
5	0	0	0	0

Pain, assessed through a subjective rating scale, showed a reduction, without however achieving any statistical significance between groups or genders: pain was reduced both with bicarbonate and with HA.

Patient satisfaction showed an increase already at the beginning of therapy (Figure 3) in both groups, but the

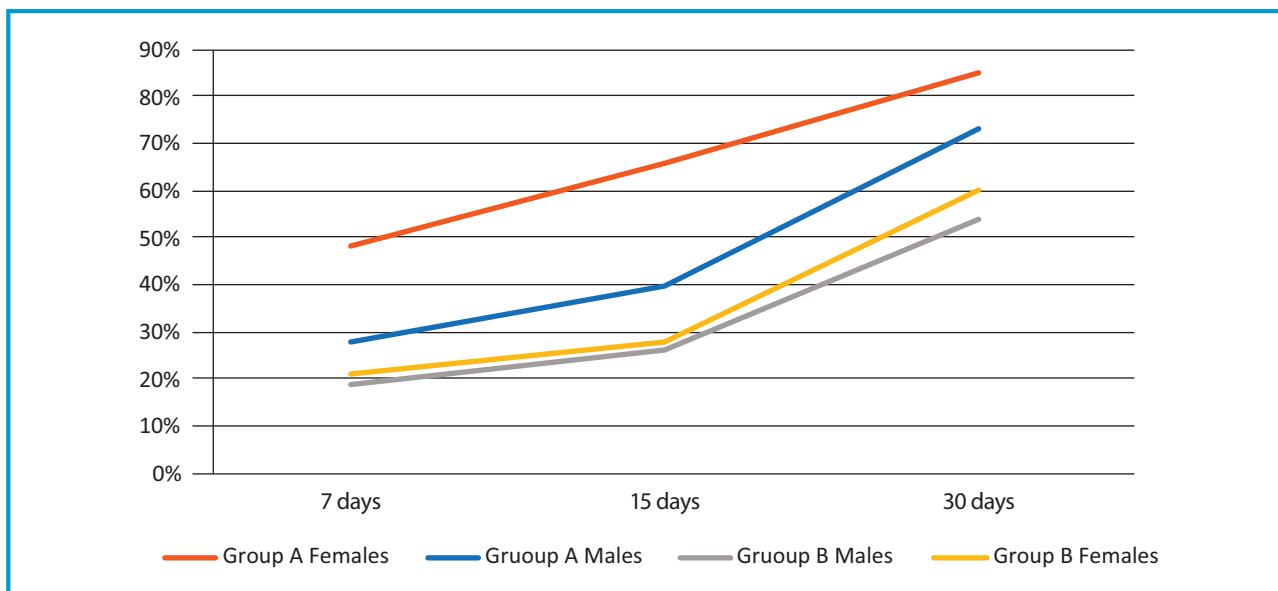


Figure 2. Improvement of mucosal objectivity (%).

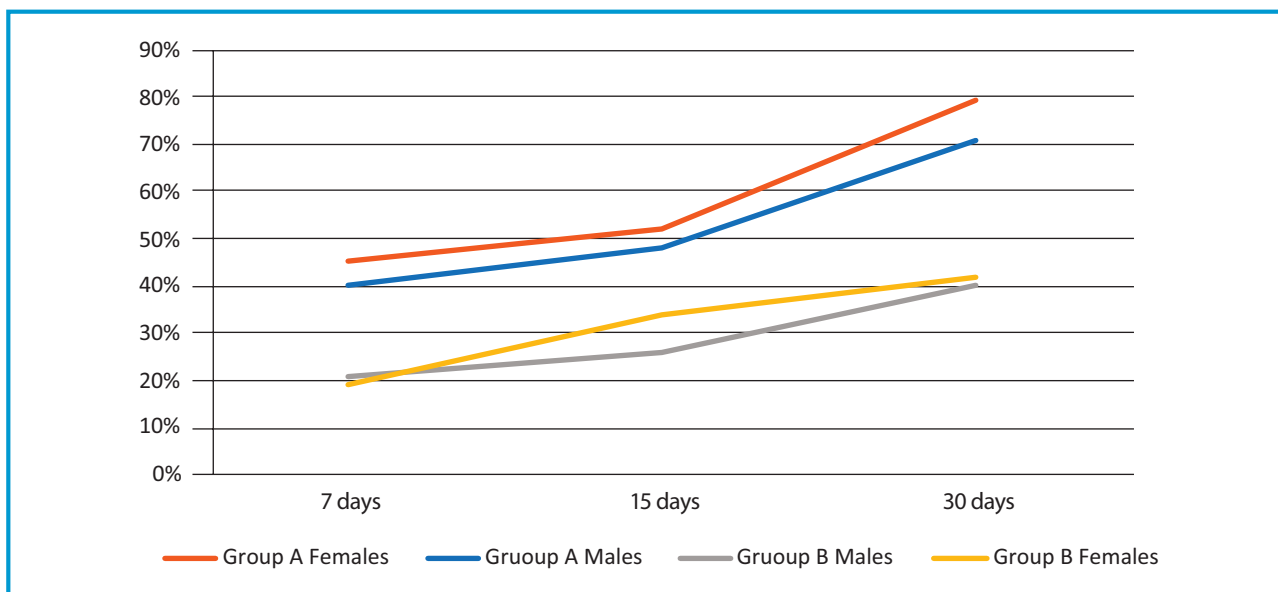


Figure 3. Subjective improvement (%).

study group showed a more marked and statistically significant increase, which was even more pronounced among women, where it reached a percentage of 79% among the women of group A versus 40% of the men in group B ($p < 0.05$).

The greater response by women than men ($p < 0.05$) is particularly evident in the study group, and increases over time. A justification for this response, in the absence of gender-inherent biological differences, could be determined by a greater adherence to therapy.

No patient experienced adverse drug reactions in the course of the study.

Discussion

Burning mouth syndrome involves a significant discomfort for the patient.

The symptomatology has a chronic course, which can be continuous or intermittent, and persists for one very variable period of time, ranging from a few months to many years.

The pathognomonic symptom is the 'burning', more often of moderate intensity, but persistent for long periods, which is difficult to tolerate. The burning can be widespread, can affect any site of the oral mucosa and

has often a multifocal – and sometimes bilateral and symmetrical – localization. The symptoms are sometimes described as a sensation of heat or burning swelling of the oral mucosa, often accompanied by a feeling of dry mouth and dysgeusia, difficulty swallowing and olfactory disturbances.

Patients are often irritable, sleepless, anxious, depressed, do not like socializing and change their eating habits.

HA finds applications in various medical fields, including orthopedic, ophthalmological, oncology and dentistry.¹⁵⁻¹⁸ Several studies have been performed in the dental field on the effectiveness of local drugs based on HA and amino acids that, once applied on the wounds of the oral cavity, lead to a rapid healing and a reduction of local pain symptoms compared to common emollient gels.^{9,19-21}

HA is a glycosaminoglycan (GAG) formed by the repetition of disaccharide units consisting of glucuronic acid and N-acetylglucosamine; it is naturally present at the level of connective tissues and gives them hydration, turgidity, plasticity and viscosity.^{22,23} Most cells have the ability to synthesize HA at some point in their cycle. The main function of HA therefore appears to be in tissue healing. In this process HA is involved in a range of activities, including the activation and modulation of inflammatory responses, the promotion of cell proliferation, migration and angiogenesis, the increase in re-epithelialization through the proliferation of basal keratinocytes, the deposition of collagen and the formation of scars. Fibroblasts are the only source of collagen, the main component of the connective tissue, and an adequate synthesis of collagen is fundamental in the healing process. As with other proteins, its synthesis completely depends on the local availability of the amino acids present in the final molecule. Glycine, L-proline and L-lysine have been found in extremely regular patterns in the collagen molecule. Lysine is inserted in a well-defined position in relation to glycine and L-proline. In fact, after assembling the triple helix of the collagen precursor, the tropo-collagen, a specific hydroxylase is activated to promote hydroxylation of proline and lysine in hydroxyproline and hydroxylysine in specific sites, to ensure inter- and intra-molecular bonds that provide cohesion, flexibility and the tensile forces characteristic of the collagen molecule.

The mechanism of action provides for the stimulation of neoangiogenesis, promoting the formation of granulation and collagen tissue by stimulating the activity of fibroblasts.²⁴⁻²⁷ The function of helping the processes of tissue regeneration depends on its high biocompatibility, through a mechanical protective action, which also allows to maintain the conditions of ideal humidity for the re-epithelialization of the injured area.²⁸⁻³⁰

These characteristics make it ideal in the treatment of mucosal lesions, and this study is aimed at assessing the effectiveness of the new compound compared to the use of a common mouthwash for the oral cavity. The product used for this study is a medical device, formulated as an oral spray. It is composed of glycine, L-proline; L-leucine, L-lysine, sodium hyaluronate, purified water and excipients.

The study group (group A) showed a more frequent improvement in mucosal objectivity already in the short term. The degree of mucous de-epithelialization and pain decreased in both groups. The significantly higher improvement in women has been empirically interpreted as greater adherence to and compliance with the proposed therapy. Patient satisfaction increases in both groups, but is statistically greater in the group of treated patients.

Several studies^{8,31,32} focused their attention on the use of HA as a topical treatment of oral mucositis. In particular, Nolan³¹ has shown that a topical application of 0.2% HA gel 2 times a day for 2 weeks seems to be an effective and safe therapy in patients with recurrent aphthous mucosal lesions.

In a retrospective clinical study, also Dalessandri² concluded that the topical gel formulation is effective in the treatment of minor recurrent aphthous stomatitis with a tendency to early healing.

Lee and others^{30,33} investigated the effectiveness of the topical application of acid gel 0.2% hyaluronic for oral ulcers in patients with recurrent ulcers and with Behcet's disease. In this study, the application of HA gel improved both subjective (number of injuries, healing period, Visual Analogue Scale – VAS – for pain) and objective parameters (number of injuries, extension of lesions and edema and local burning pain). With the data obtained from the review of 25 clinical studies, Casale and others³⁴ show that, due to its positive action on tissue repair and wound healing, topical administration of HA could play a role not only in treatment of patients undergoing dental care, but also in those suffering from chronic gingivitis or ulcers of the oral cavity, with a significant improvement in their quality of life.

In another study, Casale³⁵ once again confirms that HA has recently been proposed for topical administration in the treatment of oral ulcers and other painful oral lesions and, after systematically reviewing the published literature, the author selects and includes 4 relevant publications: two concerning oral lichen planus, one on Behcet's disease and recurrent aphthous ulcer and one on oral ulcer in general. Both subjective parameters (healing period and VAS for pain) and objective assessments (number of ulcers, maximum area of the ulcer and signs of inflammation) significantly improve after treatment with HA. These data suggest that HA can play a fundamental role in the treatment of oral ulcers.

Even the data obtained from our study shows that the association of sodium hyaluronate with amino acids can also play a role in the treatment of patients suffering from burning mouth syndrome secondary to local or general causes, with an improvement in their quality of life, thus confirming what has already emerged in literature in recent years.

The best result in women (not identified, or maybe not evaluated, in other works) can find an explanation in a better adherence.

Conclusions

Many studies on the oral mucosa show how the combination of sodium hyaluronate and amino acids plays an adjuvant role in the healing processes of the oral mucosa, which significantly promotes patients' healing and compliance; in particular, we highlighted the presence of a greater response from women than men ($p < 0.05$), which is particularly evident in the group of treated subjects and which grows over time.

In conclusion, based on the data obtained, the product under study can be recommended for a local use to reduce the degree of de-epithelialization of the mucosa. The product also seems improve the degree of satisfaction, especially among females.

Key messages

- Burning mouth syndrome is a frequently occurring manifestation, which involves an important discomfort for the patient, with a significantly higher prevalence in women.
- The symptomatology has a chronic course, which can be continuous or intermittent, and the cause can be classified as either primary or secondary to countless medical conditions.
- According to the literature, hyaluronic acid and amino acids stand out among the most recent therapeutic innovations used to facilitate the healing of the oral mucosa, while no gender-specific results have been reported or evaluated.
- The tested sodium hyaluronate and amino acids oral formulation (Mucosamin®) proved to reduce the degree of de-epithelialization of the mucosa, while improving the degree of satisfaction and reducing pain sensation.
- More relevant results were found in the female group ($p < 0.05$), following both objective and subjective evaluations; a greater adherence to therapy is likely to explain this gender difference.

References

1. Coculescu EC, Radu A, Coculescu BI. Burning mouth: a review on diagnosis and treatment. *J Med Life*. 2014;7(4):512-5.
2. Dalessandri D, Zotti F, Laffranchi L et al. Treatment of recurrent aphthous stomatitis (RAS, aphthae, canker sore) with a barrier forming mouth rinse or topical gel formulation containing hyaluronic acid: a retrospective clinical study. *BMC Oral Health*. 2019;19:153.
3. Silvestre FJ, Silvestre-Rangil J, López-Jornet P. Burning mouth syndrome: a review and update. *Rev Neurol*. 2015;60(10):457-63.
4. Cerchiarri DP, Dutra de Moricz R, Alves Sanjar F, Bogar Rapoport P, Moretti G, Michelin Guerra M. Burning mouth syndrome: etiology. *Braz J Otorhinolaryngol*. 2006;72(3):419-23.
5. Forabosco A, Negro C. La sindrome della bocca bruciante. *Minerva Stomatol*. 2003;52(11-12):507-21.
6. Padovani A, Cottini E. Sindrome della bocca urente. *Dolore cronico e neuropatico*. *Focus on Brain*. 2017;2.
7. Heckmann SM, Heckmann JG, Hilz MJ et al. Oral mucosal blood in patients with burning mouth syndrome. *Pain*. 2001;90(3):281-6.
8. Lauritano D, Spadai F, Santoro F. Problematiche eziopatogenetiche e clinico-terapeutiche della sindrome della bocca bruciante. *Il Dentista Moderno*. 2003;61-68.
9. Pilat G. Acido ialuronico per l'odontoiatria. *Italian Dental Journal*. 2009;4:20-1.
10. Price RD, Myers S, Leigh IM, Navsaria HA. The role of hyaluronic acid in wound healing: assessment of clinical evidence. *Am J Clin Dermatol*. 2005;6(6):393-402.
11. Colella G, Cannavale R, Vicidomini A, Rinaldi G, Compilato D, Campisi G. Efficacy of a spray compound containing a pool of collagen precursor synthetic aminoacids (l-proline, l-leucine, l-lysine and glycine) combined with sodium hyaluronate to manage chemo/radiotherapy-induced oral mucositis: preliminary data of an open trial. *Int J Immunopathol Pharmacol*. 2010;23(1):143-51.
12. Mendes RM, Silva GAB, Lima MF et al. Sodium hyaluronate accelerates the healing process in tooth sockets of rats. *Arch Oral Biol*. 2008; 53(12):1155-62.
13. Pirnazar P, Wolinsky L, Nachnani S, Haake S, Pilloni A, Bernard GW. Bacteriostatic effects of hyaluronic acid. *J Periodontol*. 1999;70:370-4.
14. Scardina GA, Pisano T, Messina P. La sindrome della bocca che brucia. *Recenti Prog Med*. 2007;98(2):120-8.
15. Favia G, Mariggiò MA, Maiorano E, Cassano A, Capodiferro S, Ribatti D. Accelerated wound healing of oral soft tissues and angiogenic effect induced by a pool of aminoacids combined to sodium hyaluronate (AMINOGAM). *J Biol Regul Homeost Agents*. 2008;22(2):109-16.
16. Mesa FL, Aneiros, Cabrera A et al. Antiproliferative of topic hyaluronic acid gel. Study in gingival biopsies of patients with periodontal disease. *Histol Histopathol*. 2002; 17(3):747-53.
17. Ortonne JP. Comparative study of the activity of hyaluronic acid and dextranomer in the treatment of leg ulcers of venous origin. *Ann Dermatol Venereol*. 2001;Suppl 13-16.

18. Soldati D, Rahm F, Pasche P. Mucosal wound healing after nasal surgery. A controlled clinical trial on the efficacy of hyaluronic acid containing cream. *Drugs Exp Clin Res.* 1999;25(6):253-61.
 19. Pogrel MA, Lowe MA, Stern R. Hyaluronan (hyaluronic acid) in human saliva. *Arch Oral Biol.* 1996;41(7):667-71.
 20. Vescovi P, Manfredi M, Ripasarti A et al. Effects of amino acids and sodium hyaluronate (Aminogam) in the post-operative period after surgical laser treatment of oral lesions: a pilot study. [Internet]. Available from: www.professionaldietetics.com
 21. Varki A, Cummings RD, Esko JD et al. *Essentials of glyco-biology*. 2nd ed. Cold Spring Harbor Laboratory Press. 2008.
 22. Kobayashi H, Terao T. Hyaluronic acid-specific regulation of cytokines by human uterine fibroblasts. *Am J Physiol.* 1997;273(4):C1151-9.
 23. Mariggì MA, Cassano A, Vinella A et al. Enhancement of fibroblast proliferation, collagen biosynthesis and production of growth factors as a result of combining sodium hyaluronate and aminoacids. *Int J Immunopathol Pharmacol.* 2009;22(2):485-92.
 24. Adamo D, Sardella A, Varoni E et al. The association between burning mouth syndrome and sleep disturbance: a case-control multicentre study. *Oral Dis.* 2018;24(4):638-49.
 25. Chen WYJ, Abatangelo G. Functions of hyaluronan in wound repair. *Wound Repair Regen.* 1999;7(2):79-89.
 26. Chimenos-Küstner E, De Luca-Monasterios F, Schemel Suárez M et al. Burning mouth syndrome and associated factors: a case-control retrospective study. *Med Clin.* 2017; 148:153-7.
 27. Greco RM, Iocono JA, Ehrlich HP. Hyaluronic acid stimulates human fibroblast proliferation within a collagen matrix. *J Cell Physiol.* 1998;177(3):465-73.
 28. Chimenos-Küstner E, Marques-Soares MS. Burning mouth and saliva. *Med Oral.* 2002;7(4):244-53.
 29. Jentsch H, Pomowski R, Kundt G, Göcke R. Treatment of gingivitis with hyaluronan. *J Clin Periodontol.* 2003;30(2): 159-64.
 30. Lee JH, Jung JY, Bang D. The efficacy of topical 0.2% hyaluronic acid gel on recurrent oral ulcers: comparison between recurrent aphthous ulcers and the oral ulcers of Beçhet's disease. *J Eur Acad Dermatol Venereol.* 2008;22(5):590-5.
 31. Nolan A, Baillie C, Badminton J, Rudralingham M, Seymour RA. The efficacy of topical hyaluronic acid in the management of recurrent aphthous ulceration. *J Oral Pathol Med.* 2006;35(8):461-5.
 32. Sennhenn-Kirchner S, Jacobs HG. Traumatic injuries to the primary dentition and effects on the permanent successors. A clinical follow-up study. *Dent Traumatol.* 2006;22(5): 237-41.
 33. Lee YH, Chon S. Burning mouth syndrome in post-menopausal women with self-reported sleep problems. *Cranio.* 2020;38(4):221-32.
 34. Casale M, Moffa A, Vella P et al. Systematic review: the efficacy of topical hyaluronic acid on oral ulcers. *J Biol Regul Homeost Agents.* 2017;31(4, Suppl 2):63-9.
 35. Casale M, Moffa A, Vella P et al. Hyaluronic acid: perspectives in dentistry. A systematic review. *Int J Immunopathol Pharmacol.* 2016;29(4):572-82.
- Author contribution statement:* all the Authors have participated, read and approved the final version of the article.
- Conflict of interest statements:* all Authors declare no conflicts of interest.
- Ethic statement:* the study was conducted in accordance with the ethical standards of the 1964 Helsinki declaration and its later amendments and comparable ethical standards.
- Informed consent:* all the patients had offered written informed consent to reproduce and publish data and photographs.
-
- Correspondence to:*
Laura Lanza
Department of Otorhinolaryngology
Vigevano and Voghera Hospitals – ASST Pavia
Corso Milano 19
27029 Vigevano (PV), Italy
email Laura_Lanza@asst-pavia.it