

Managing cardiac arrest secondary to spontaneous coronary artery dissection: should we routinely consider ICD implantation? Insights from the Parma SCAD registry

Rossella Giacalone^{1*}, Marco Toselli^{2*}, Giovanna Pelà³, Maria Alberta Cattabiani¹, Antonella Vezzani⁴, Giorgio Benatti¹, Iacopo Tadonio¹, Marco Ferretti⁵, Filippo Luca Gurgoglione⁵, Davide Rizzello⁵, Maniola Noni¹, Giampaolo Niccoli⁵, Diego Ardissino⁵, Luigi Vignali¹, Emilia Solinas¹

¹Division of Cardiology, Parma University Hospital, Parma, Italy; ²GVM Care and Research, Maria Cecilia Hospital, Interventional Cardiology Unit Cotignola, Ravenna, Italy; ³Department of Medicine and Surgery, University of Parma, Italy; ⁴Cardiac Surgery Intensive Care Unit, Parma University Hospital, Parma, Italy; ⁵Division of Cardiology, University of Parma, Parma University Hospital, Parma, Italy

*These Authors contributed equally to this work as leading authors.

Received 14 January 2022; accepted 2 May 2022

Summary. *Background.* Cardiac arrest secondary to a spontaneous coronary artery dissection (SCAD) represents a challenging scenario. *Methods.* We collected clinical data from four women admitted in the Coronary Care Unit (CCU) of the Parma University Hospital over the last two years for cardiac arrest with the angiographic diagnosis of SCAD. *Results.* Three patients survived the acute phases. One patient, being considered at high risk of SCAD recurrence, received a subcutaneous implantable cardioverter-defibrillator (S-ICD). *Conclusions.* The acute management of cardiac arrest related to SCAD deserves specific consideration. The residual myocardial damage and the predisposing and precipitants factors should be evaluated, in order to estimate the SCAD recurrence and sudden cardiac death risks.

Keywords. Spontaneous coronary artery dissection, gender, outcomes/studies, sudden cardiac death, diagnostic algorithms, prevention strategies.

Introduction

Spontaneous coronary artery dissections (SCAD) account for a small proportion of acute coronary syndromes (ACS) in the general population. However, in younger individuals, especially younger women with few or no traditional cardiovascular risk factors, SCAD is more prevalent, and increasingly recognized as a cause of ACS.^{1,2} SCAD is caused by a non-traumatic and non-iatrogenic separation of the coronary arterial walls by intramural hematoma or spontaneous intimal tear, which can lead to luminal narrowing, occlusion, and eventually result in myocardial ischemia.¹

The clinical presentation of SCAD is highly variable. Chest pain is the most frequently reported symptom, seen in 60-90% of patients. However, atypical symptoms – including ‘burning sensation’ (9%), ‘pleurisy’ (3%), ‘tearing’ (1%), and ‘positional pain’ (1%) – are reported in a minority of patients.³

SCAD almost always occurs as either ST-segment elevation myocardial infarction (STEMI) or non-ST-seg-

ment elevation myocardial infarction (NSTEMI), which can lead to cardiogenic shock, malignant arrhythmias and sudden cardiac death. Although the overall prognosis of patients surviving SCAD is relatively good, ventricular tachycardia or ventricular fibrillation at presentation account for as much as 8.1% of cases.⁴

Methods

We herein present a case series of four women (age range 48-60 years) admitted to the Coronary Care Unit (CCU) of the Parma University Hospital with SCAD complicated by cardiac arrest due to ventricular fibrillation (VF) (Table 1 and Table 2) over the last two years.

Results

Case 1

A 48-year-old woman, with no traditional cardiovascular risk factors and no relevant past medical history, was admitted to our hospital for a cardiac arrest due to ventricular fibrillation. Bystander cardiopulmonary resuscitation (CPR) was delivered early and return of spontaneous circulation (ROSC) was achieved after two direct-current shocks (DCs), delivered by the attending paramedics.

Post-arrest electrocardiogram (ECG) did not show any signs of acute ischemia, and no neurological deficit was evident. Invasive coronary angiography was performed four days later, detecting a spontaneous dissection of the distal circumflex artery, with thrombolysis in myocardial infarction (TIMI) 3 flow (type 2 Saw classification) (Figure 1 – Panel 1), in the absence of atherosclerotic coronary artery lesions. A conservative strategy of dual antiplatelet therapy (DAPT) with acetylsalicylic acid and clopidogrel was adopted. Following the diagnostic algorithm for SCAD,⁵ cardiac magnetic resonance (CMR) was performed during the hospitalization, which

Table 1. SCAD clinical and angiographic features

	Age (yrs)	ECG post CA	Time to angiogram (hours)	Involved coronary	SCAD type	TIMI flow (distal to the SCAD)	Conservative management	Outcome
Case 1	48	No ischemic changes	96	LCX distal	2	3	Yes	Survived
Case 2	60	Inferior ST elevation	2	LCX distal	2	2	Yes	Survived
Case 3	53	No ischemic changes	36	LAD mid	4	1	Yes	Survived
Case 4	57	Anterior ST elevation	3	LAD mid	2	2	Yes	Died

SCAD: spontaneous coronary artery dissection, ECG: electrocardiogram, CA: cardiac arrest; TIMI: thrombolysis in myocardial infarction, LCX: left circumflex artery, LAD: left anterior descending artery.

Table 2. SCAD therapy, predisposing recurrence factors, sudden cardiac death prevention and follow-up

	DAPT (C + A)	CMR	Angio-CT	Fibromuscular dysplasia	ICD implantation	Follow-up
Case 1	yes	Posterior wall SE-DE	Dissecting aneurysm of RVA	Yes	Yes	Unremarkable
Case 2	yes	Posterior wall SE-DE	Normal	No	No	Unremarkable
Case 3	yes	Anterior wall TM-DE	Normal	No	No	Unremarkable
Case 4	-	-	-	-	-	-

SCAD: spontaneous coronary artery dissection, DAPT: dual antiplatelet therapy, C: clopidogrel, A: acetylsalicylic acid, CMR: cardiac magnetic resonance, CT: computed tomography, ICD: implantable cardiac defibrillator, SE: sub-endocardial, DE: delay enhancement, RVA: right vertebral artery, TM: trans-mural.

revealed a hyper intense signal in the T2w/STIR sequences, consistent with edema in the inferolateral wall, associated with subendocardial late gadolinium enhancement in the same region. Given the possible association of SCAD with fibromuscular dysplasia (FMD), a whole body vascular computed tomography (CT) angiography was also performed, which revealed a dissecting aneurysm of the right vertebral artery. In consideration of the initial presentation with VF, combined with the evidence of extra coronary arteriopathy, the patient was deemed at high risk of SCAD recurrence and, following a team discussion, the consensus was to implant a subcutaneous cardioverter-defibrillator (S-ICD), for the secondary prevention of sudden cardiac death (SCD). No recurrent cardiovascular events were reported at a 1-year follow-up.

Case 2

A 60-year-old woman, with no cardiovascular risk factors and no prior medical history, developed chest pain and nausea at rest, followed by a cardiac arrest. By-stander CPR was commenced, and paramedics confirmed VF

and restored ROSC following four DCs. The ECG showed inferior ST elevation, so endo-tracheal intubation (ETI) was performed, and the patient was transported to our hospital. An emergency coronary angiography revealed a slight narrowing of the distal circumflex artery, suspicious for a type 2 SCAD (Figure 1 – Panel 2a). Due to the small caliber of the involved segment and the high risk of percutaneous coronary intervention (PCI) in SCAD, a conservative approach was adopted. DAPT was initiated and, after clinical stabilization, the patient was rapidly extubated. A CMR revealed thinning and hypokinesia of the posterior left ventricular wall, associated with subendocardial edema and delayed enhancement (<50% of wall thickness). Contrast CT angiography revealed no abnormalities of the extra coronary vascular beds. At the 6- and 12-month follow-up the patient was asymptomatic, with no disease recurrence.

Case 3

A 53-year-old woman with hypertension, but no other relevant comorbidities, developed cardiac arrest second-

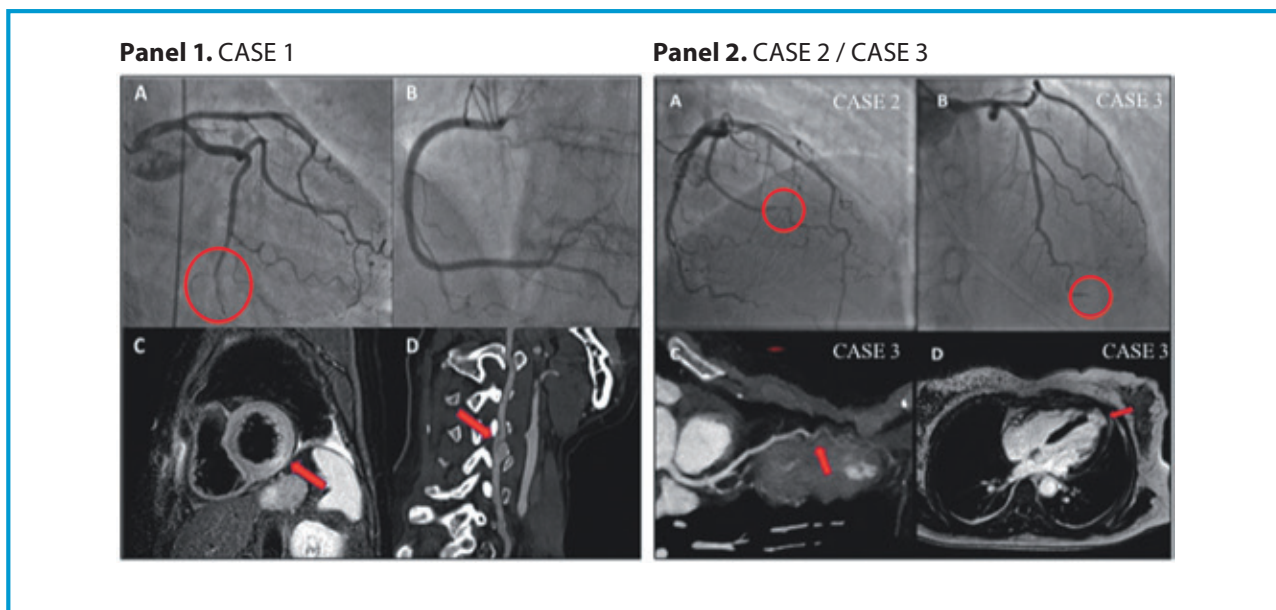


Figure 1. Panel 1. CASE 1. A: coronary angiogram right-caudal view: diameter mismatch in the distal left circumflex coronary artery, suspected for type 2 SCAD (red circle) and B no lesions in the right coronary artery. C: cardiac MRI showing subendocardial edema in the inferolateral left ventricular wall on T2 STIR sequences (red arrow). D: cervical angio-CT showing a dissecting aneurysm of the right vertebral artery (red arrow). Panel 2. A: CASE 2 coronary angiogram showing type 2 SCAD (red circle) or first obtuse marginal branch. B: CASE 3 coronary angiogram, showing narrowing and total occlusion of distal left anterior descending (LAD) artery (type 4 SCAD). C: computed tomography coronary angiography from the same patient confirming distal LAD dissection (red arrow) and D cardiac MRI showing transmural late gadolinium enhancement of the apical left ventricular (red arrow).

ary to VF, while sitting at her office desk. Resuscitation was rapidly initiated by trained colleagues, with successful ROSC achieved after 6 minutes of CPR and a single DCs. Glasgow Coma Score remained 7 and ETI was performed. The patient was admitted to the Intensive Care Unit, where a head CT scan ruled out acute injuries. The following day, she developed ischemic ECG changes associated with apical dyskinesia. An emergency coronary angiography showed a mid-segment left anterior descending artery lesion suspicious of SCAD, which resulted in a total occlusion of the apical recurrent branch (type 4 SCAD) (Figure 1 – Panel 2 b, c, d). A CT angiography did not show any other vascular abnormality, and confirmed the angiographic findings of coronary dissection. A CMR showed apical transmural delayed enhancement with aneurysmal remodeling. After 13 days, the patient was discharged on DAPT and at the 6- and 12-month follow-up she was asymptomatic, with no recurrences.

Case 4

A 57-year-old woman with no traditional cardiovascular risk factors and no prior medical history experienced an out-of-hospital cardiac arrest. Bystander CPR was started and multiple DCs were required to treat refractory VF. An automatic chest compression system was applied and ETI was performed; the patient was transferred to the Intensive Care Unit, where the ECG showed anterior

ST-segment elevation. An emergency coronary angiography showed tortuous coronary anatomy with a type 2 SCAD affecting the mid left anterior descending artery (Figure 2). Given the preserved distal coronary flow (TIMI 2) and considering the unfavorable anatomy and the absence of hemodynamic or electrical instability, a non-invasive strategy was chosen. In the following days, the patient remained hemodynamically stable, however significant post-anoxic neurological damages developed, due to the prolonged resuscitation period. After a few days, cerebral death was declared.

Discussion

SCAD represents an important cause of myocardial infarction in younger individuals with few or no traditional cardiovascular risk factors, especially women. The recognition of this condition has been more frequent in recent years, due to the increased awareness of physicians and interventional cardiologists, the advancements of invasive and non-invasive imaging technologies, and the increased sensitivity of troponin essays. Reported prevalence accounts for less than 1% of all-comers ACS cases, according to recently published registries, which excluded atherosclerotic-related dissections.⁶ However, the true prevalence remains unclear, due to potential under- or missed diagnosis.

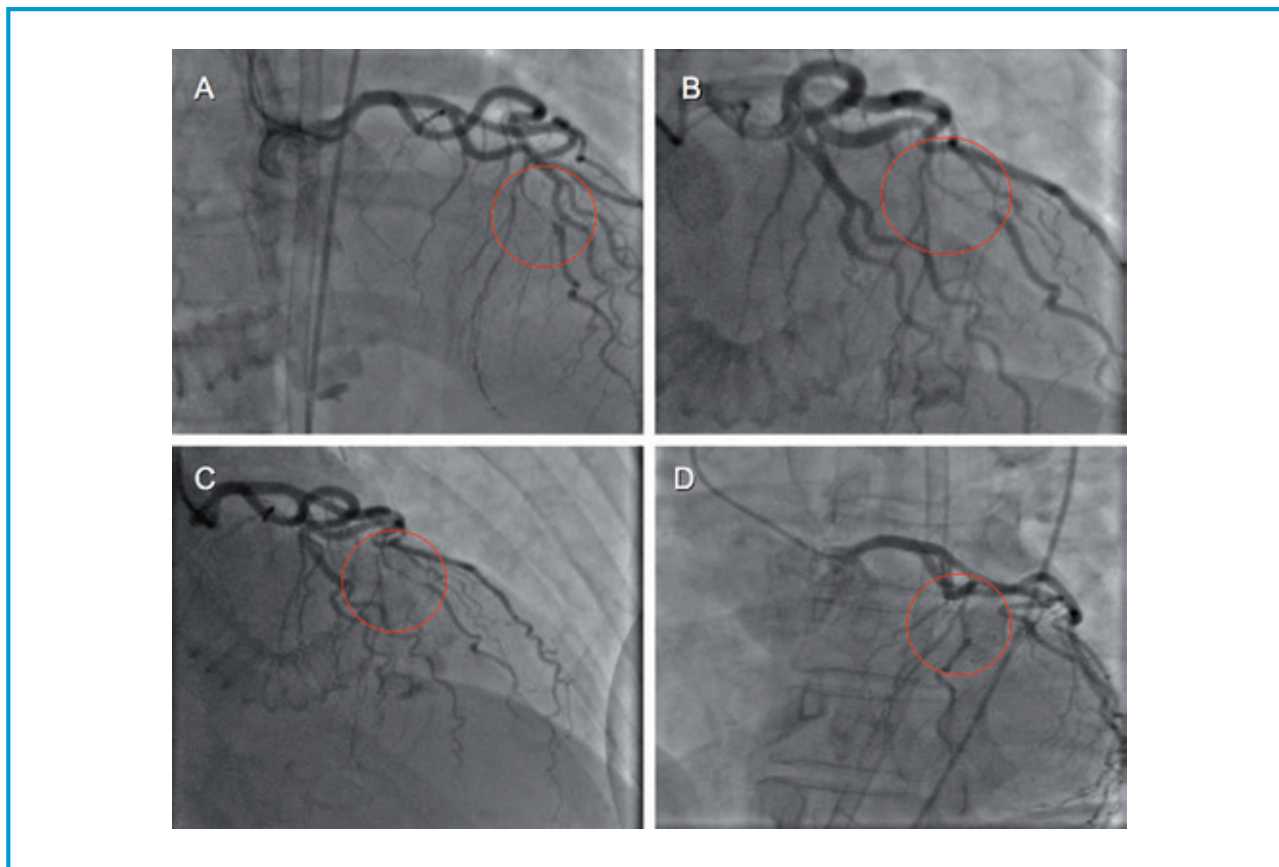


Figure 2. CASE 4. A, B, C, D: multiple views of coronary angiogram showing type 2 SCAD (red circle) of mid left anterior descending coronary artery.

The epidemiology of the disease is characterized by a strong female predominance, which is believed to depend on hormonal influences. This correlation is supported by the increased incidence observed during pregnancy.⁷ Furthermore, SCAD is frequently associated with various arteriopathies, of which FMD – a non-atherosclerotic non-inflammatory disorder that involves multiple arterial beds – is the commonest. Long-term survival for patients surviving SCAD is up to 92% at a 10 years follow-up, with recurrence of SCAD occurring in 29.4% of the subjects.⁸ However, several studies have demonstrated a significant rate of major cardiovascular events at follow-up (47% at 10 years).

Acute management of the cardiac arrest related to SCAD

The management of SCAD-related cardiac arrest deserves specific consideration, due to the dramatic presentation and the need for secondary SCD prevention (Figure 3A).

In a recent study, analyzing a nationwide database of patients hospitalized for acute myocardial infarction, SCAD was complicated by cardiac arrest in 4.3% of cases. It occurred almost three times more frequently than

non-SCAD ACS.⁹ Our case series illustrates the importance of prompt resuscitation maneuvers and early defibrillation. If stable ROSC cannot be achieved, the activation of a mechanical circulatory support (MCS) team should be considered.

Guidelines emphasize the usefulness of an early coronary angiography strategy in establishing the diagnosis and evaluating the need for an interventional approach.¹⁰ In the presence of ambiguous angiographic findings, intracoronary imaging (intravascular ultrasound – IVUS and optical coherence tomography – OCT) can help clarify the underlying disease process.¹¹ It is worth noting that SCAD usually heals spontaneously within a few months.¹²

Revascularization procedures in patients with SCAD are very challenging, and PCI is associated with a high rate of failure and coronary complications.^{13,14} Therefore, the decision should be individualized and, in stable conditions, a conservative management should be prioritized. However, patients with SCAD involving left main or proximal coronary segments – especially with type-4 SCAD (total occlusion) or with a TIMI flow 0/1 below the lesion, or with electrical/hemodynamic instability or recurrent ischemia – may benefit from PCI.^{1,15}

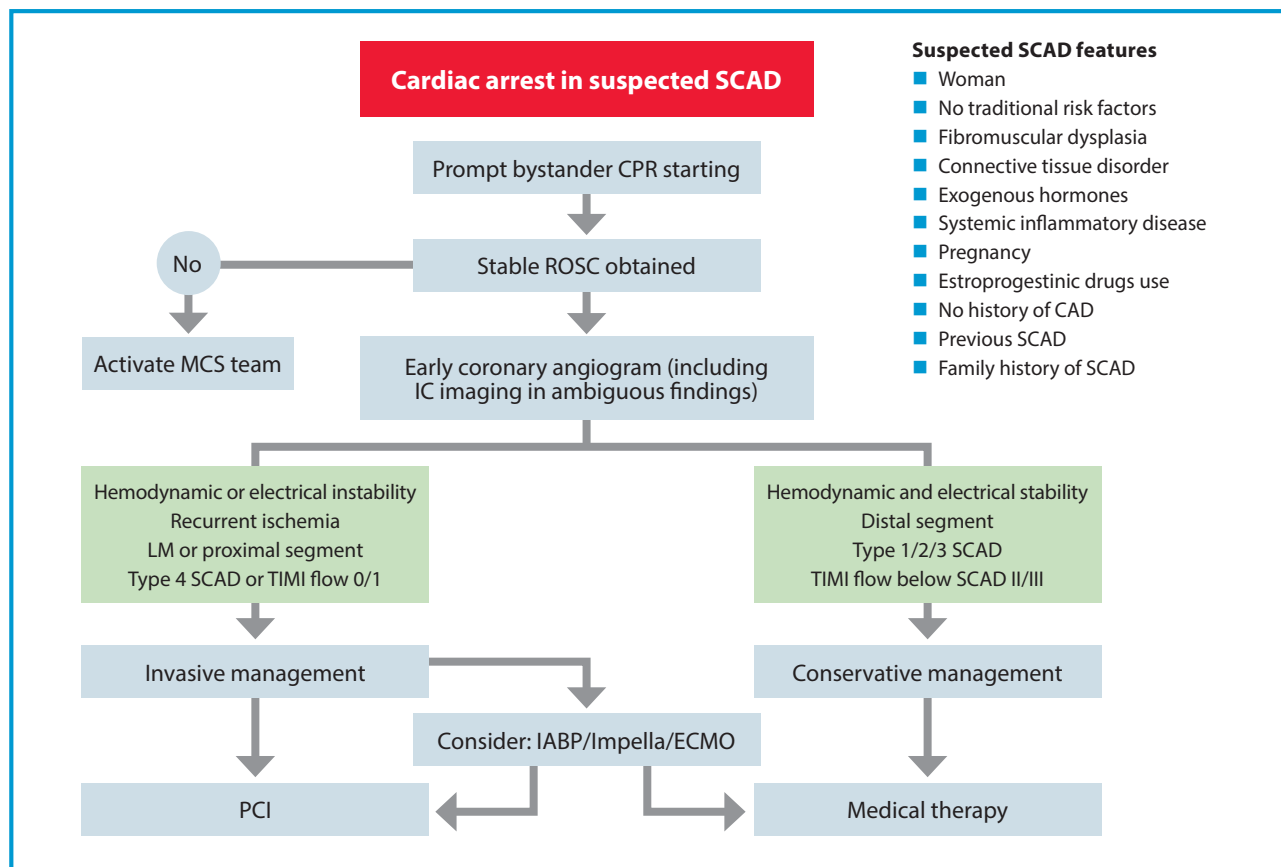


Figure 3A. Acute management of cardiac arrest related to SCAD.

Revascularization strategies are not standardized in these settings, and different approaches have been proposed, including plain old balloon angioplasty (POBA), direct stenting or the use of a cutting balloon to facilitate dissipation of the intramural hematoma.¹⁶

On the basis of the scientific evidence and the suggestions derived from the position papers issued by the leading scientific societies, we decided to design an algorithm that can guide the clinician in the choice of the most appropriate operative strategy in the case of SCA with elevated suspicion of SCAD (Figure 3A). This suspicion must be included when the SCA affects a young woman, without a history of heart disease, in pregnancy or in the peripartum period, or a young subject with a history of autoimmune disease. After performing the resuscitation maneuvers according to advanced cardiovascular life support (ACLS) and obtaining a stable ROSC, we recommend proceeding with an emergency coronary angiography, even in the absence of clear signs of ischemia on the post-arrest ECG. In the hemodynamic laboratories equipped with intracoronary imaging methods (IVUS - OCT) – and in the presence of sufficiently experienced operators – we suggest their routine use, in order to improve diagnostic accu-

racy. In more complex cases, with refractory arrhythmias or hemodynamic instability, early intervention by MCS team should be considered, and the use of circulus support, such as intra-aortic balloon pump (IABP), Impella or extracorporeal membrane oxygenation (ECMO) should be implemented to support an interventional strategy such as PCI or coronary artery bypass graft surgery (CABG).

Evaluating the risk of SCAD recurrence and sudden cardiac death

The management of SCAD patients complicated by malignant ventricular arrhythmias and cardiac arrest is challenging. The risk-benefit ratio of ICD implantation in these patients remain uncertain.¹⁷ Current guidelines support ICD therapy for the secondary prevention of sudden cardiac death only in the absence of reversible causes and for primary prevention in patients with severely impaired left ventricular ejection fraction (LVEF).^{18,19} Evaluation of scar burden with CMR can help stratify the global arrhythmic risk, especially since an extensive myocardial scar with a residual impaired LVEF increases the risk of future arrhythmic events (Figure 3B).

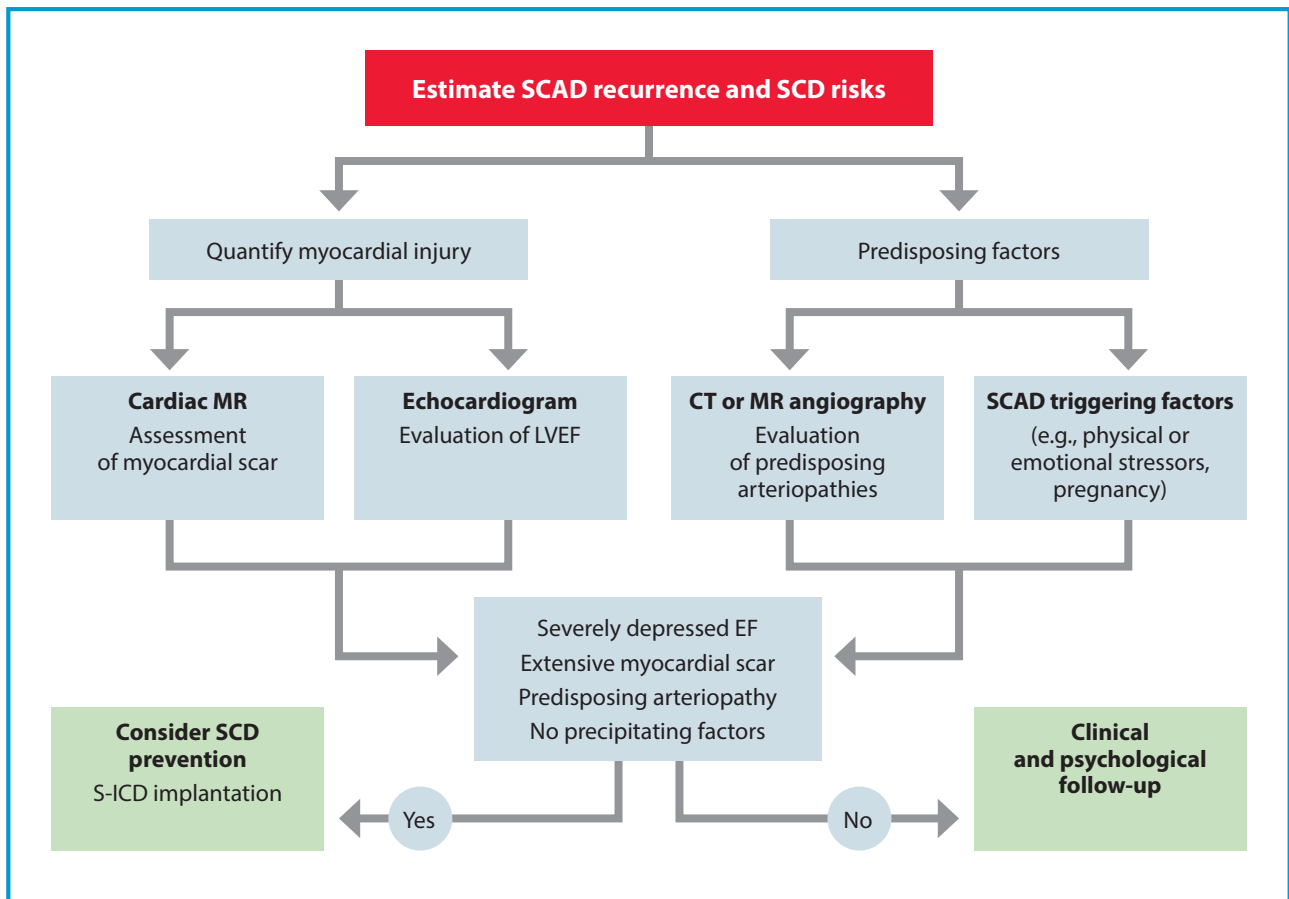


Figure 3B. Evaluating risk of SCAD recurrence and sudden cardiac death.

SCAD lesions usually heal spontaneously and LVEF is often preserved in this population, or recovers shortly after the acute event. However, in light of the high SCAD recurrence rate and the relatively young age at presentation, it is reasonable to make further considerations.

Looking at the published registries, it appears that SCAD patients are more likely to suffer from ventricular arrhythmia or sudden cardiac death than non-SCAD MI patients. In addition, a recent observational study reported that 12.3% of all 30-day readmissions after SCAD were due to arrhythmias.⁹ The decision to implant an ICD is not without risks. In this regard, opting for a S-ICD can be a reasonable choice, due to the equal efficacy and lower complications rate compared to the traditional devices.²⁰ In our series, only one patient underwent S-ICD implantation, and the decision was mainly driven by the finding of underlying arteriopathy affecting other vascular territories, suggesting a potentially higher rate of SCAD recurrence.

For this particular subset of patients, we propose an algorithm that combines predisposing factors and myocardial injury quantification data (Figure 3B), that could

be useful for the estimate of the risk of malignant arrhythmias, as well as the risk of recurrence of SCAD, but which needs to be validated in larger case studies.

All patients surviving SCA due to ventricular tachyarrhythmias should undergo a transthoracic echocardiogram for the LVEF estimation and a CMR for scar research and its quantification. To improve the risk of sudden cardiac death recurrence prediction, we recommend the routine use of CT angiography or vascular MRI angiography of the cerebral and abdominal district, to search for any predisposing arteriopathies (e.g., FMD).^{21,22} Furthermore, a careful medical history, the possibility of psychological counseling and specific follow-up programs should be implemented for these patients, in order to identify other predisposing factors. Through these instruments, it is possible to trace a population with a higher risk of arrhythmic relapse and in whom the choice of protection from sudden death with an ICD may be appropriate. The characteristics we have traced are a low LVEF at presentation which does not improve before discharge, an extensive ischemic damage evidenced by extensive myocardial scar, the presence of predisposing arterial disease and the absence of trigger-

ing factors. In the presence of one or more of these characteristics, the patient should be evaluated by a multidisciplinary team involving an electrophysiologist for the implantation of an ICD. Where technically possible, a subcutaneous device (s-ICD) should be preferred, due to the less invasiveness of the surgery and the lower rate of complications. This choice is also clinically supported, given the few arrhythmic relapses in these patients over the course of their life, for which infrequent interventions on the part of the device are expected.

Conclusions

In conclusion, the evidence on the management of SCAD patients presenting with aborted sudden cardiac death is still scarce, and the risk-benefit ratio of ICD therapy in these patients is debatable, especially in patients with evidence of extra-coronary vascular abnormalities. More studies and data from observational registries and clinical trials are needed, because only a constant and larger effort by the scientific community could expand our knowledge and support the best clinical practice on this relatively rare, but potentially malignant pathology. The development and validation of a novel risk score in this particular population could be very useful tool in the clinical decision of ICD implantation.

References

1. Saw J, Mancini GBJ, Humphries KH. Contemporary review on spontaneous coronary artery dissection. *J Am Coll Cardiol.* 2016;68(3):297-312.
2. Tweet MS, Gulati R, Hayes SN. Spontaneous coronary artery dissection. *Curr Cardiol Rep.* 2016;18(7):60.
3. Luong C, Starovoytov A, Heydari M, Sedlak T, Aymong E, Saw J. Clinical presentation of patients with spontaneous coronary artery dissection. *Cathet Cardiovasc Intervent.* 2017;89(7):1149-54.
4. Saw J, Starovoytov A, Humphries K, Sheth T, So D, Minhas K et al. Canadian spontaneous coronary artery dissection cohort study: in-hospital and 30-day outcomes. *Eur Heart J.* 2019;40(15):1188-97.
5. Basso C, Aguilera B, Banner J, Cohle S, d'Amati G, de Gouveia RH et al. Guidelines for autopsy investigation of sudden cardiac death: 2017 update from the Association for European Cardiovascular Pathology. *Virchows Arch.* 2017;471(6):691-705.
6. Nakashima T, Noguchi T, Haruta S, Yamamoto Y, Oshima S, Nakao K et al. Prognostic impact of spontaneous coronary artery dissection in young female patients with acute myocardial infarction: a report from the Angina pectoris-myocardial infarction multicenter investigators in Japan. *Int J Cardiol.* 2016;207:341-8.
7. Tweet MS, Lewey J, Smilowitz NR, Rose CH, Best PJM. Pregnancy-associated myocardial infarction: prevalence, causes,

Abbreviations

ACLS	advanced cardiovascular life support
ACS	acute coronary syndrome
CABG	coronary artery bypass graft surgery
CAD	coronary artery dissection
CCU	coronary care unit
CMR	cardiac magnetic resonance
CPR	cardiopulmonary resuscitation
CT	computed tomography
DAPT	dual antiplatelet therapy
DCs	direct-current shocks
ECG	electrocardiogram
ECMO	extracorporeal membrane oxygenation
EF	ejection fraction
ETI	endo-tracheal intubation
FMD	fibromuscular dysplasia
IABP	intra-aortic balloon pump
IVUS	intravascular ultrasound
LVEF	left ventricular ejection fraction
MCS	mechanical circulatory support
MR	magnetic resonance
OCT	optical coherence tomography
PCI	percutaneous coronary intervention
POBA	plain old balloon angioplasty
ROSC	return of spontaneous circulation
SCAD	spontaneous coronary artery dissection
SCD	sudden cardiac death
SCA	sudden cardiac arrest
S-ICD	subcutaneous implantable cardioverter-defibrillator
STEMI	ST-segment elevation myocardial infarction
TIMI	thrombolysis in myocardial infarction
VF	ventricular fibrillation

Key messages

- SCAD appears to be more common in females, with few or no traditional cardiovascular risk factors, compared to males.
- SCAD in most cases occurs as acute coronary syndrome (STEMI or NSTEMI), more rarely as cardiac arrest due to malignant ventricular arrhythmias.
- An algorithm can guide the clinician in the choice of the most appropriate operative strategy in the case of SCA with elevated suspicion of SCAD: prompt resuscitation maneuvers, early defibrillation, early coronary angiography strategy, intracoronary imaging and interventional approach if suitable.
- The risk-benefit ratio of ICD implantation in these patients remain uncertain and evaluation of scar burden with CMR can help stratify the global arrhythmic risk.
- An algorithm that combines predisposing factors like FMD and myocardial injury quantification data could be useful for the estimate of the risk of malignant arrhythmias, as well as the risk of recurrence of SCAD, but needs to be validated in larger case studies.

- and interventional management. *Circ Cardiovasc Interv.* 2020.
8. Tweet MS, Hayes SN, Pitta SR, Simari RD, Lerman A, Lennon RJ et al. Clinical features, management, and prognosis of spontaneous coronary artery dissection. *Circulation.* 2012;126(5):579-88.
 9. Gad MM, Mahmoud AN, Saad AM, Bazarbashi N, Ahuja KR, Karthik AK et al. Incidence, clinical presentation, and causes of 30-day readmission following hospitalization with spontaneous coronary artery dissection. *JACC Cardiovasc Interv.* 2020;13(8):921-32.
 10. Hayes SN, Kim ESH, Saw J, Adlam D, Arsianian-Engoren C, Economy KE et al. Spontaneous coronary artery dissection: current state of the science. A scientific statement from the American heart association. *Circulation.* 2018;137(19):e523-e557.
 11. Motreff P, Malcles G, Combaret N, Barber-Chamoux N, Bouajila S, Pereira B et al. How and when to suspect spontaneous coronary artery dissection: novel insights from a single-center series on prevalence and angiographic appearance. *EuroIntervention.* 2017;12(18):e2236-e2243.
 12. Rogowski S, Maeder MT, Weilenmann D, Haager PK, Ammann P, Rohner F et al. Spontaneous coronary artery dissection: angiographic follow-up and long-term clinical outcome in a predominantly medically treated population. *Cathet Cardiovasc Intervent.* 2017;89(1):59-68.
 13. Tweet MS, Eleid MF, Best PJM, Lennon RJ, Lerman A, Rihal CS et al. Spontaneous coronary artery dissection: revascularization versus conservative therapy. *Circ Cardiovasc Interv.* 2014;7(6):777-8.
 14. Martins JL, Afreixo V, Santos L, Costa M, Santos J, Gonçalves L. Medical treatment or revascularisation as the best approach for spontaneous coronary artery dissection: a systematic review and meta-analysis. *Eur Heart J Acute Cardiovasc Care.* 2018;7(7):614-23.
 15. Collet JP, Thiele H, Barbato E, Barthélémy O, Bauersachs J, Bhatt DL et al. 2020 ESC guidelines for management of acute coronary syndromes in patients presenting without persistent ST-segment elevation. *Eur Heart J.* 2021;42(14):1289-1367.
 16. Adlam D, Alfonso F, Maas A, Vrints C, Writing Committee. European Society of Cardiology, Acute Cardiovascular Care Association, SCAD study group: a position paper on spontaneous coronary artery dissection. *Eur Heart J.* 2018;39(36):3353-68.
 17. Sharma S, Rozen G, Duran J, Mela T, Wood MJ. Sudden cardiac death in patients with spontaneous coronary artery dissection. *J Am Coll Cardiol.* 2017;70(1):114-5.
 18. Al-Khatib SM, Stevenson WG, Ackerman MJ, Bryant WJ, Callans DJ, Curtis AB et al. 2017 AHA/ACC/HRS guideline for management of patients with ventricular arrhythmias and the prevention of sudden cardiac death: executive summary. *Heart Rhythm.* 2018;15(10):e190-e252.
 19. Priori SG, Blomström-Lundqvist C, Mazzanti A, Blom N, Borggrefe M, Camm J et al. 2015 ESC guidelines for the management of patients with ventricular arrhythmias and the prevention of sudden cardiac death: the task force for the management of patients with ventricular arrhythmias and the prevention of sudden cardiac death of the European Society of Cardiology (ESC). Endorsed by: Association for European Paediatric and Congenital Cardiology (AEPC). *Eur Heart J.* 2015;36(41):2793-867.
 20. Weiss R, Knight BP, Gold MR, Leon AR, Herre JH, Hood M et al. Safety and efficacy of a totally subcutaneous implantable-cardioverter defibrillator. *Circulation.* 2013;128(9):944-53.
 21. Saw J, Aymong E, Seoedlak T, Buller CE, Starovoytov A, Ricci D et al. Spontaneous coronary artery dissection: association with predisposing arteriopathies and precipitating stressors and cardiovascular outcomes. *Circ Cardiovasc Interv.* 2014;7(5):645-55.
 22. Liang JJ, Prasad M, Tweet MS, Hayes SN, Gulati R, Breen JF et al. A novel application of CT angiography to detect extracoronary vascular abnormalities in patients with spontaneous coronary artery dissection. *J Cardiovasc Comput Tomogr.* 2014;8(3):189-97.
- Ethics approval:* data present in this article derived from 'PARMA SCAD registry', that has been approved from local ethics committee, and the research was conducted in accordance with the WMA Helsinki Declaration.
- Informed consent:* the Authors confirm that a written consent for submission and publication of this case report – including images and associated text – has been obtained from the patients, in line with COPE guidance.
- Author contribution statement:* all Authors have participated in the work, and have been involved in drafting and revising it. All Authors read and approved the final version of the paper.
- Conflict of interest statement:* the Authors declare no conflicts of interest.
-
- Correspondence to:*
Rossella Giacalone
 Division of Cardiology
 Parma University Hospital
 via Antonio Gramsci 14
 43126 Parma - PR, Italy
 email: rossella.giacalone1@gmail.com